



# THE USE OF DIODE LASER FOR OFFICE HYSTEROSCOPIC POLYPECTOMY: OUR EXPERIENCE



Authors: GRECO Francesca, SORRENTINO Felice, PALIERI Tea, COCCO Ilenia, DE PADOVA Maristella, NAPPI Luigi

Department of Medical and Surgical Sciences, Institute of Obstetrics and Gynaecology, University of Foggia, Foggia, Italy

## BACKGROUND

Endometrial polyps are a common gynecological disorder, clinically characterized by abnormal uterine bleeding, infertility and related to pre-malignant and malignant lesions<sup>1,2</sup>. The incidence reported in the literature is estimated to be 24%<sup>3</sup>. Hysteroscopy is the gold standard technique for diagnosis and treatment of endometrial polyps in an office-based setting, without patient discomfort<sup>4</sup>. Recently, gynecologists experienced in operative hysteroscopy have developed a great interest in the use of surgical devices, such as lasers<sup>5</sup>. In particular, the laser diode has attracted high interest.



A diode is an electronic laser incorporating an optical gain medium in a resonant optical cavity. A system controlled by a microprocessor regulates the electrical current flow through the diode generating the laser beam. This beam is then passed through an optical system to an optical fiber, which is the medium through which light reaches the surgical site. This highly compact diode laser features the combination of two wavelengths, 980nm and 1470 nm, giving a contemporary absorption in H<sub>2</sub>O and hemoglobin (Hb) with an excellent ability of hemostasis, cutting, and vaporization.

## AIM OF THE STUDY

Our aim is to evaluate the benefits of minimally invasive techniques in hysteroscopy, focusing on the use of diode laser in the treatment of endometrial polyps.

## MATERIALS AND METHODS

50 patients with ultrasound diagnosis of endometrial polyp with maximum diameter 2.5 cm were recruited from January to April 2021. The patient was placed in a dorsal lithotomy position, and a 4-mm continuous-flow office hysteroscope (Bettocchi Office Hysteroscope "size 4" Karl Storz, Tuttlingen, Germany) with a 2.9-mm rod lens optic was introduced into the cervical canal using the vaginoscopic approach, with no speculum and tenaculum, in an office setting, with no anesthesia or sedation.

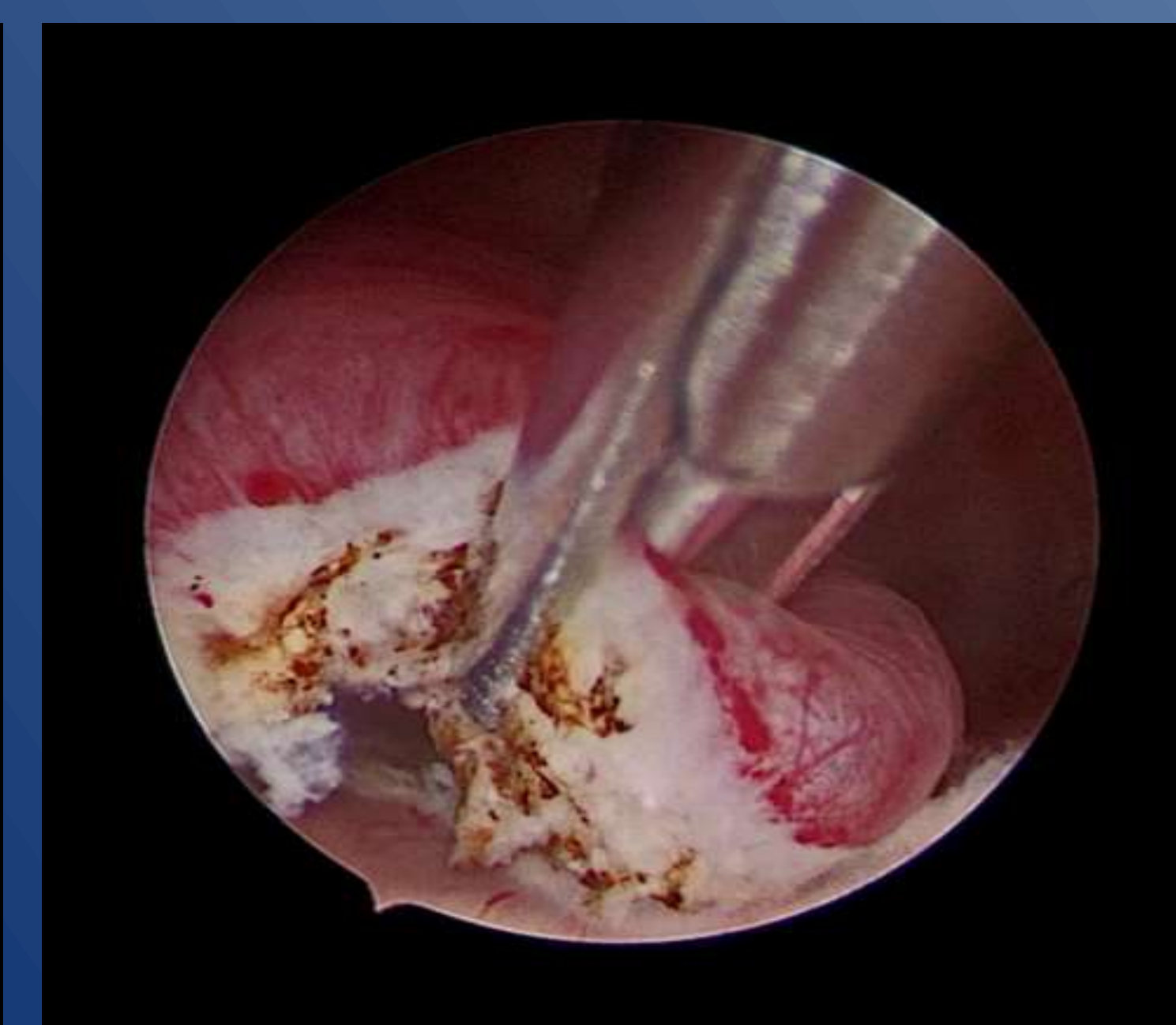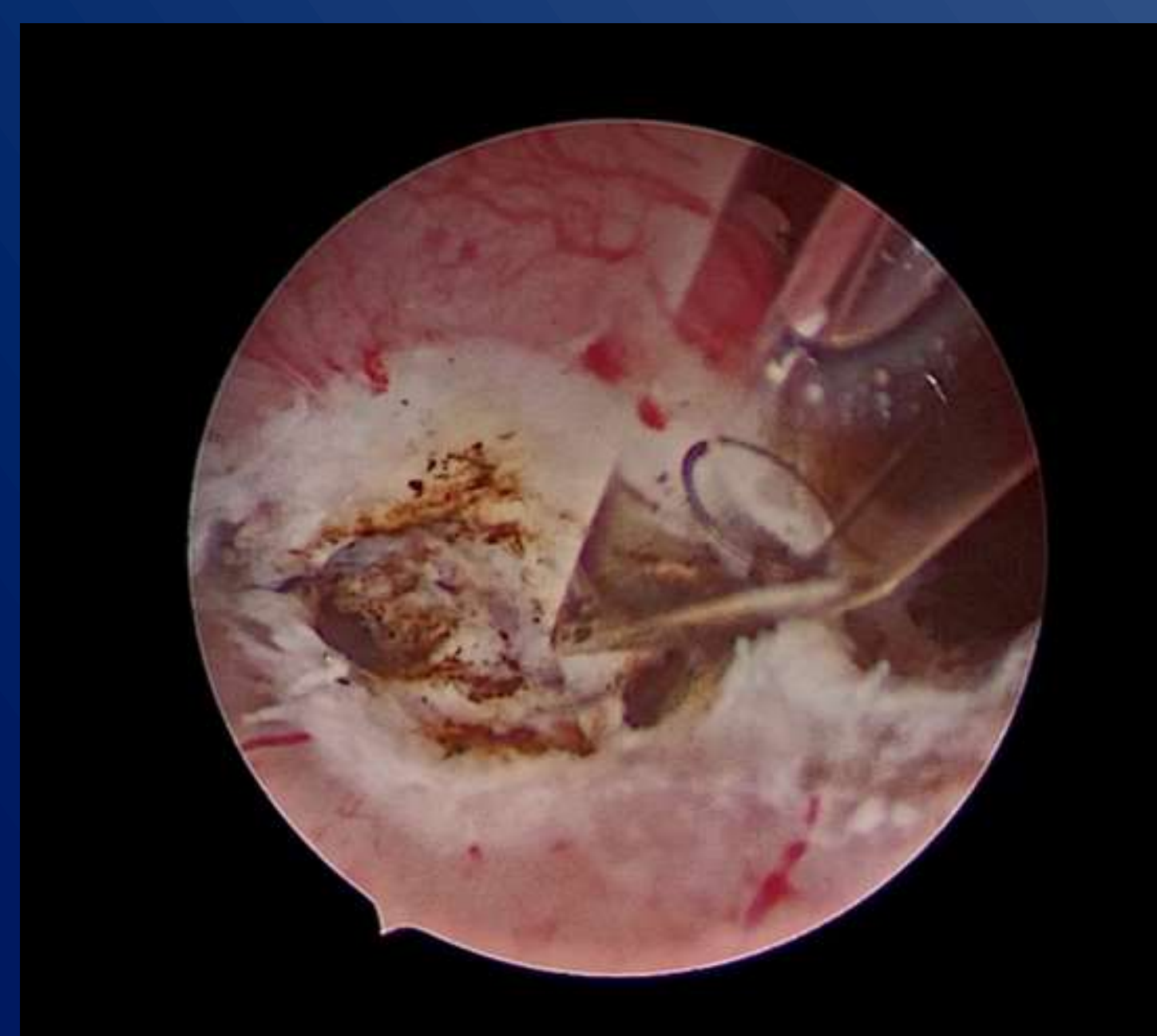
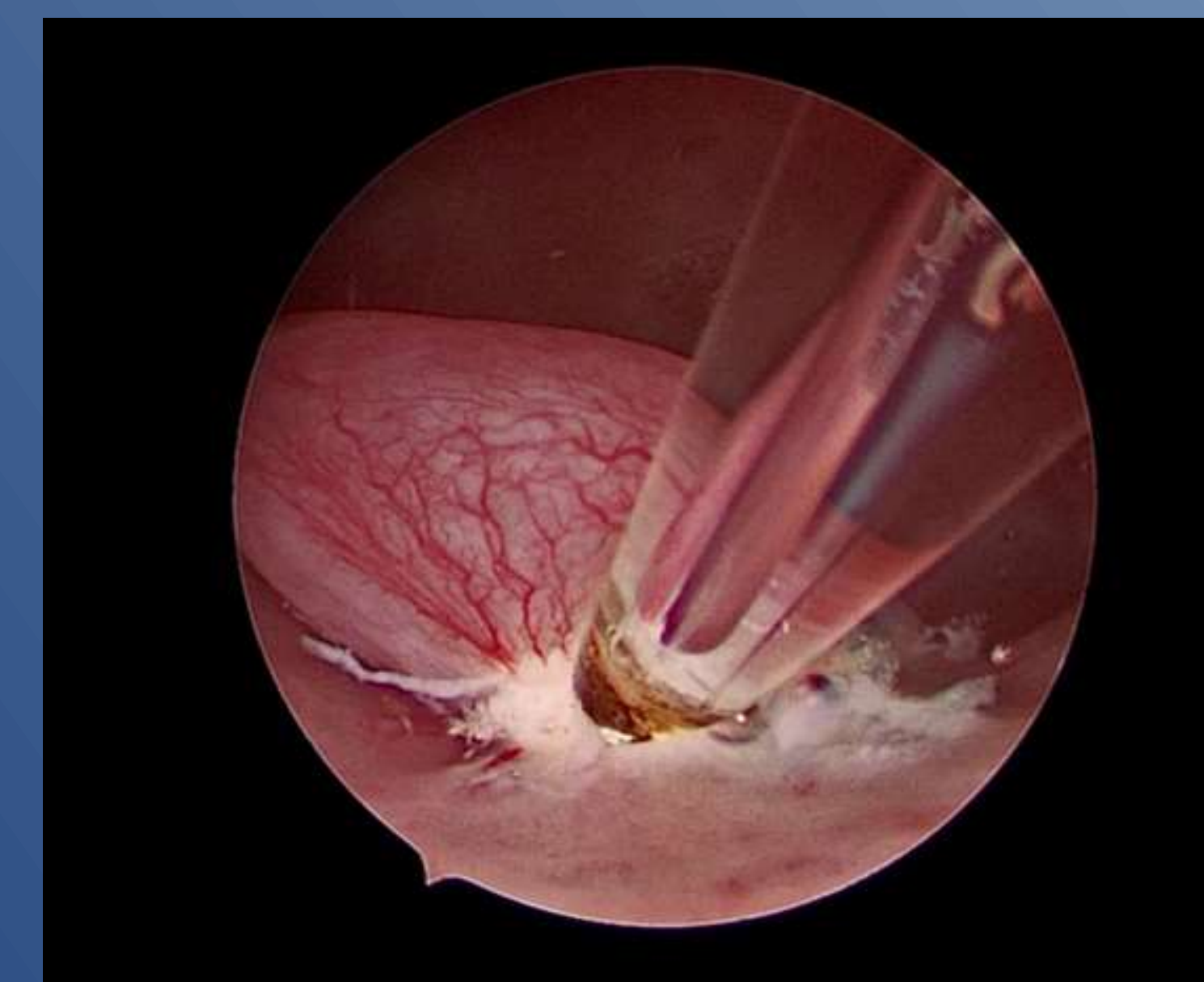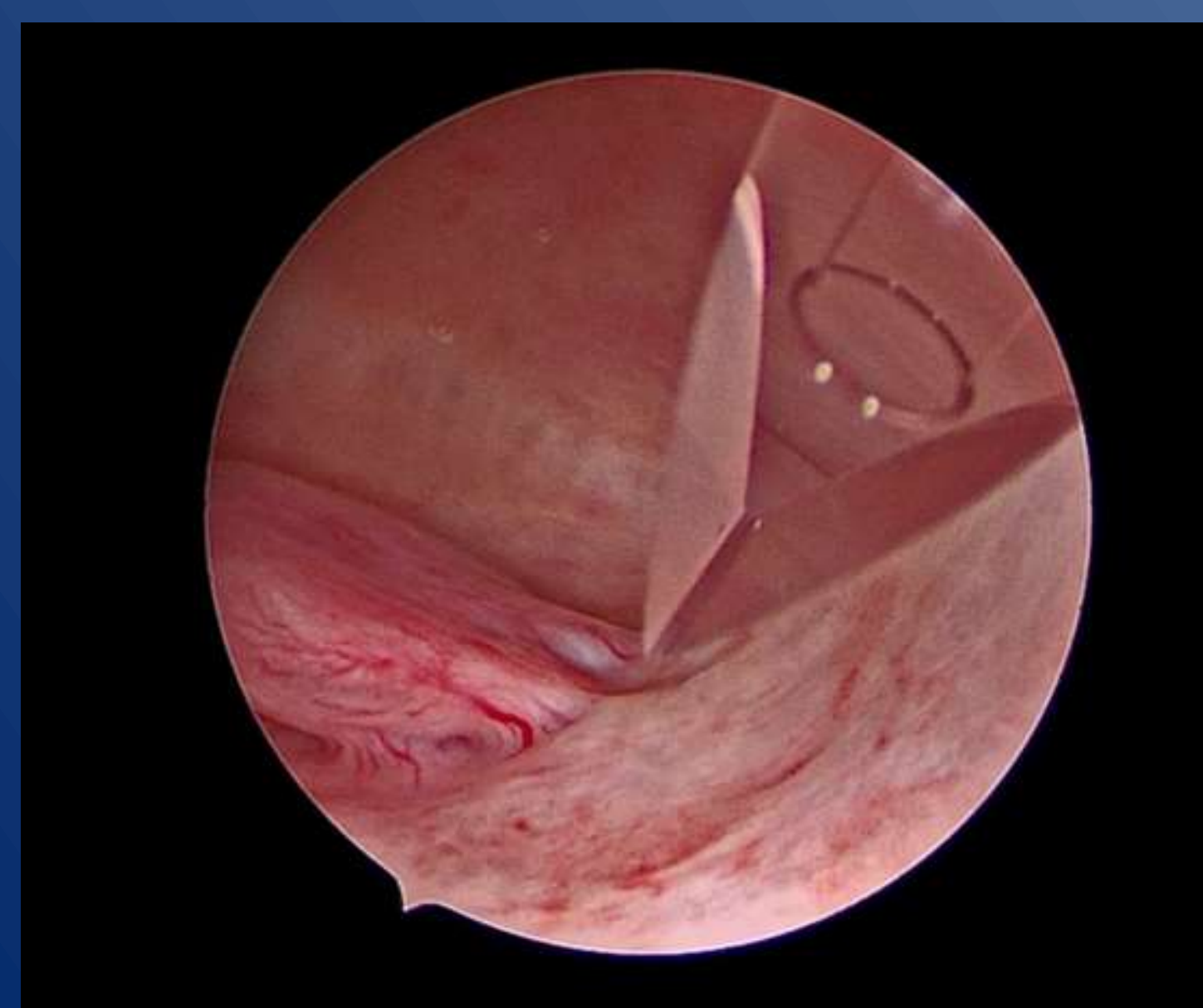
We used a new Dual wavelengths Laser System (Leonardo® Dual 45, Biolitec, Germany).

We collected data of the operative time and pain assessment was analyzed with VAS score.

Polyp resection was performed with diode laser featuring the combination of two wavelengths, 980nm and 1470 nm. The procedure was carried out without anesthesia and antibiotic prophylaxis was not administered.

## RESULTS

Operating time was  $7 \pm 1,05$  minutes. Blood loss during the procedure was minimal. There were no intraoperative complication. Intraoperative pain was  $2,72 \pm 0,51$  VAS score. No postoperative complications were observed.



## CONCLUSION

Office hysteroscopic polypectomy can be successfully performed using a diode laser. It could be a feasible and safe alternative to the scissor, bipolar twizzle and resectoscope techniques. Further well-designed studies are necessary, however, to explore the feasibility and reproducibility of the technique by other authors.

The Authors declares that there is no conflict of interest

## REFERENCES

1. Lenci MA, Nascimento VA, Grandini AB, Fahmy WM, Depes Dde B, Baracat FF, Lopes RG. Premalignant and malignant lesions in endometrial polyps in patients undergoing hysteroscopic polypectomy. *Einstein (Sao Paulo)*. 2014 Jan-Mar;12(1):16-21. doi: 10.1590/s1679-45082014ao2764. PMID: 24728240; PMCID: PMC4898233.
2. Gkrozou F, Dimakopoulos G, Vrekoussis T, Lavasidis L, Koutlas A, Navrozoglou I, Stefos T, Paschopoulos M. Hysteroscopy in women with abnormal uterine bleeding: a meta-analysis on four major endometrial pathologies. *Arch Gynecol Obstet*. 2015 Jun;291(6):1347-54. doi: 10.1007/s00404-014-3585-x. Epub 2014 Dec 19. PMID: 25524536.
3. Miranda SM, Gomes MT, Silva ID, Girão MJ. Pólipos endometriais: aspectos clínicos, epidemiológicos e pesquisa de polimorfismos [Endometrial polyps: clinical and epidemiological aspects and analysis of polymorphisms]. *Rev Bras Ginecol Obstet*. 2010 Jul;32(7):327-33. Portuguese. doi: 10.1590/s0100-72032010000700004. PMID: 21152841.
4. Bettocchi S, Ceci O, Nappi L, Di Venere R, Masciopinto V, Pansini V, Pinto L, Santoro A, Cormio G. Operative office hysteroscopy without anesthesia: analysis of 4863 cases performed with mechanical instruments. *J Am Assoc Gynecol Laparosc*. 2004 Feb;11(1):59-61. doi: 10.1016/s1074-3804(05)60012-6. PMID: 15104833.
5. Nappi L, Sorrentino F, Angioni S, Pontis A, Greco P. The use of laser in hysteroscopic surgery. *Minerva Ginecol*. 2016 Dec;68(6):722-6. Epub 2016 Feb 23. PMID: 26954490.